Clinical observations and success rates of the orthodontic anchor screw in maxillary tuberosity

Takuma Fukumoto[1)], Masaru Yamaguchi [2)], Shinichi Fukasawa[2)],
Ryo Nakajima[2)], Kunihiko Yamada[2)]

[1)] Fukumoto Orthodontic Office , [2)]Ginza Orthodontic Office

The authors have no conflicts of interest directly relevant to the content of this article.

Introduction

The orthodontic anchor screw (OAS) not only free orthodontists from anchorage-demanding cases, but they also enable clinicians to have good control over tooth movement in 3 dimensions.

However, there are the potential risks and complications of OAS such as root injury, disturbing of molar distraction.

On the other hand, recent studies reported that placement OAS in maxillary tuberosity were anatomically safe, and efficient tooth movement were archived mechanically.

However, the success rate of orthodontic anchor screw (OAS) in maxillary tuberosity has not been yet elucidated.

Objectives

The objective of this study was to evaluate the success rates of orthodontic anchor screw (OAS) in maxillary tuberosity used for lingual appliance.

En masse retraction

Aims

In this study, the OASs were inserted in maxillary tuberosity for lingual appliance. We examined whether the maxillary tuberosity is a suitable position for the placement of OAS in the lingual appliance.

Molar Distalization

Materials and Methods

- A total of 84 OASs

（Dual Pitch Anchor Screw Japan,YDM.co,Tokyo,Japan,2.0mm diameter,12mm length,　dual pitch cutting soft tapered shape ,self-drilling Type）

- 52 patients (4 males, 48 females, aged 21-50 years: 33.56±8.04) were retrospectively examined.
- The OASs that could be maintained for orthodontic anchorage for more than 6 months were considered to be successful.
- The direction of placement and bone-OAS contact (BOC) rate and OAS survival were measured using by CBCT.
- Statistical evaluation included analysis of the measured values, minimum, maximum, means, and standard deviations of the means.

Dual Pitch Anchor Screw



a. Head（2.7㎜）
b. Collar（2.0㎜）

c. Micro thread（5.5㎜）
d. Tip thread （4.5㎜）

diameter 2.0㎜
Length 12.0㎜

Result 1. Presence of third molar in maxilla

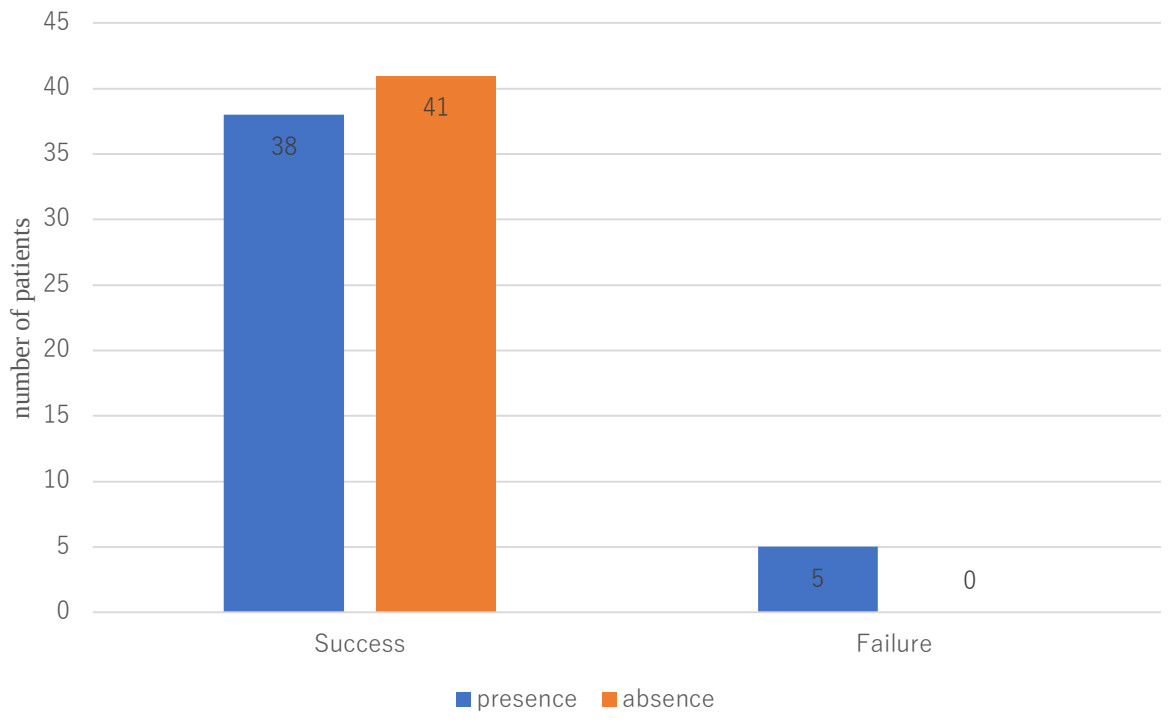

	Success	Failure
presence	38	5
absence	41	0

Result 2. rate of maxillary sinus perforation

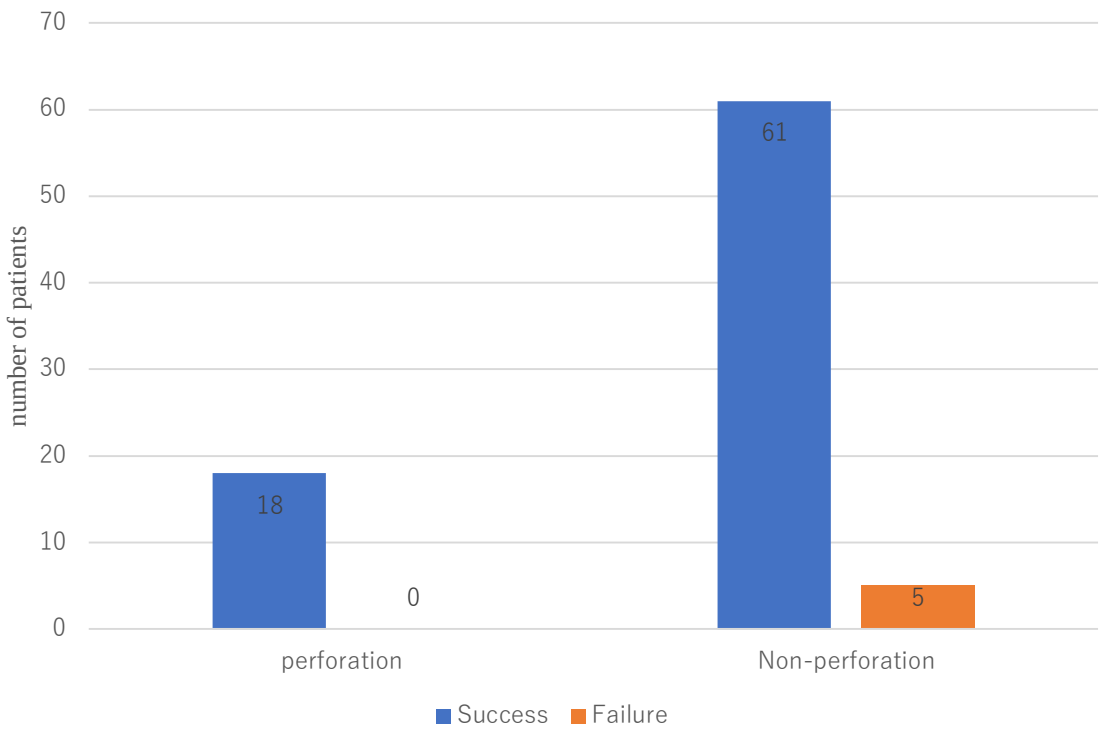

	Success	Failure
perforation	18	0
Non-perforation	61	5

Result 3. The direction of placement

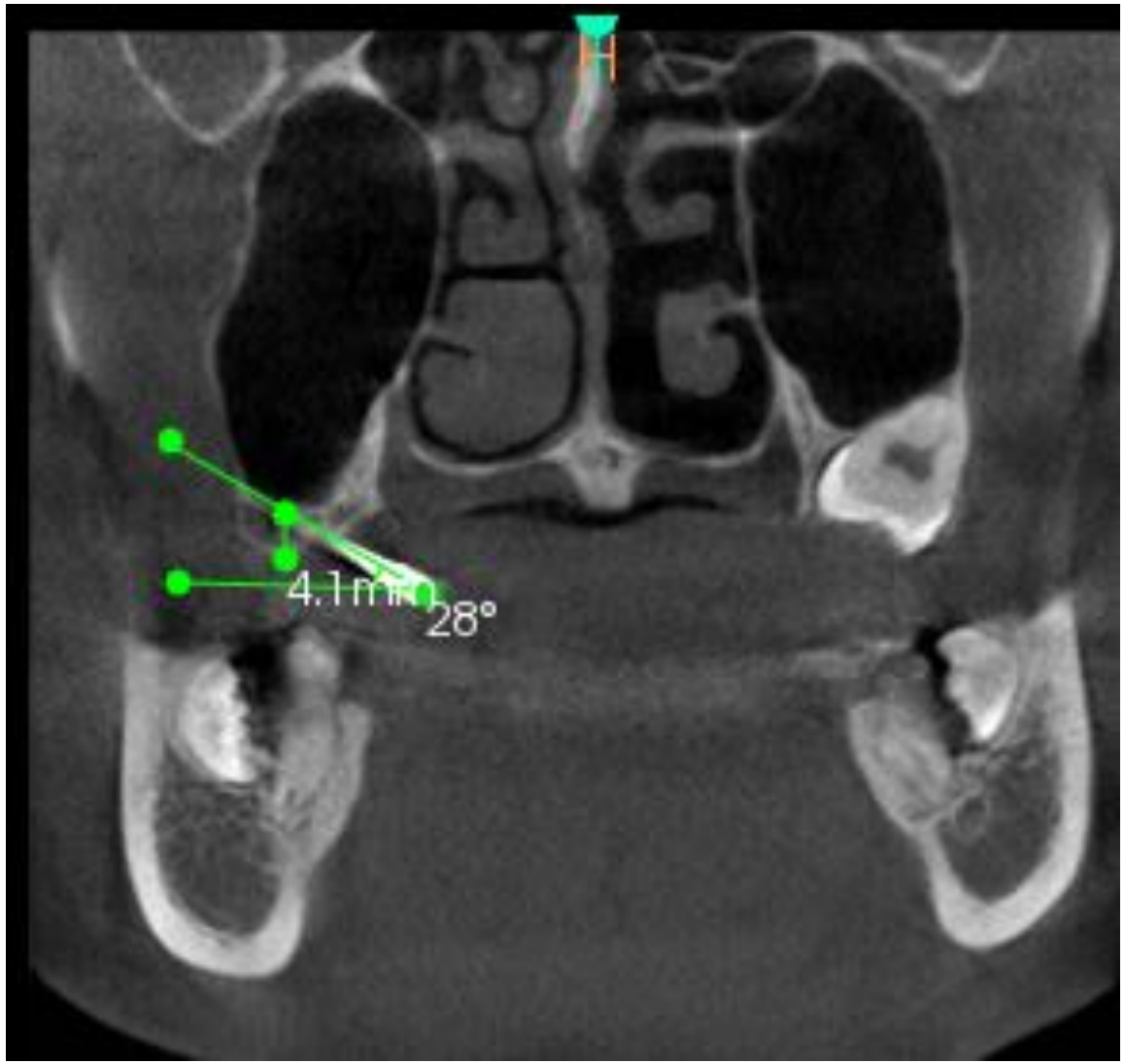

- The direction of placement was 37.9 ± 7.91° above the horizontal plane

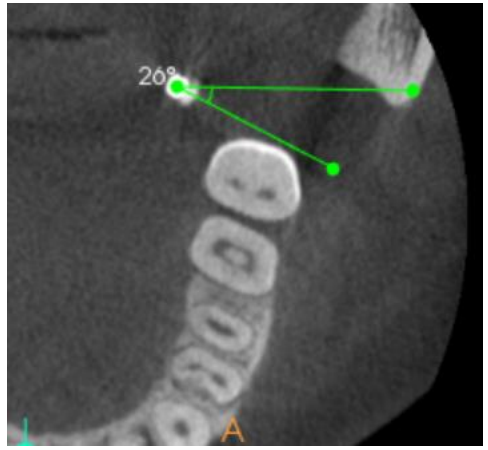

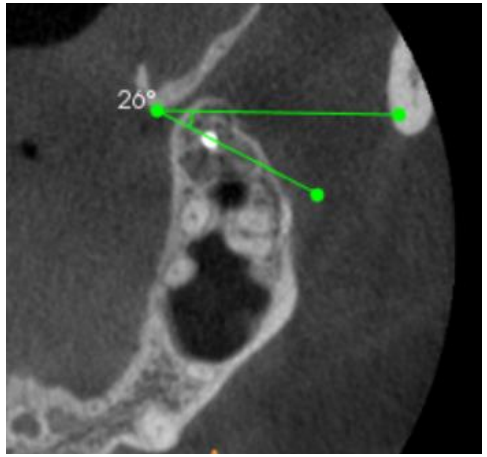

- The direction of placement was 14.8 ± (SD: 8.33) in front of the coronal plane.

Result 4. Bone-OAS Contact (BOC) rate

BOC rate 63.3% ⇒Success

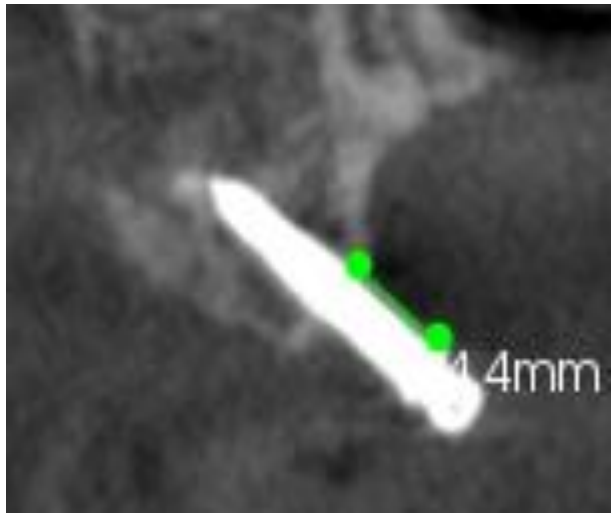

- **Implant length 12㎜**
- **Bone holding length 7.6㎜**
- **BOC rate 63.3%**

BOC rate 19.2% ⇒ Failure

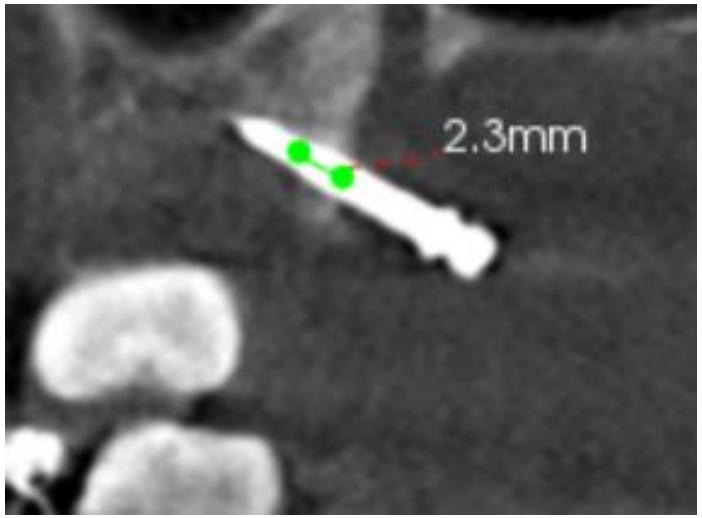

- **Implant length 12㎜**
- **Bone holding length 2.3㎜**
- **BOC rate 19.2%**

Summary of Results

- The direction of placement was 37.9±7.91° above the horizontal plane and was 14.8±(SD: 8.33) in front of the coronal plane.

- The BOC rate was 48.0±17.57%. The overall success rate was 91.4%. All of the 5 failures were inserted after extraction of wisdom teeth and BOC rate were less than 20%. The clinical variables sex, age, and side did not show significant differences in the success rate.

Conclusion

- The success rates of OASs in maxillary tuberosity showed as well as that of other position.

- Therefore, placement in maxillary tuberosity of an orthodontic anchor screw may be one of the effective means for lingual appliance.